

# Radiofrequency-assisted Liposuction for Neck and Lower Face Adipodermal Remodeling and Contouring

Evangelos Keramidas, MD, EBOPRAS,\*† Stavroula Rodopoulou, MD, EBOPRAS\*†

**Background:** The purpose of this study is to report our experience using radiofrequency-assisted liposuction (RFAL) for neck and face contouring. This article details the operative technique, selection, complications, third-party surgeon appraisal, and patient satisfaction survey.

**Methods:** From November 2009 to November 2013, 55 patients who underwent RFAL treatment were enrolled in the study. Postoperative patient satisfaction surveys were conducted, and 2 independent plastic surgeons evaluated contour and skin quality with randomized preoperative and postoperative photographs at 6 months postoperatively. The different parameters recorded involved age, sex, weight, body mass index, operative time, amount of fat aspirated and energy delivered, complications, and aesthetic outcome in 1 and 4 weeks and 3 and 6 months. Our longest follow-up was 4 years. Patients were asked 6 months postoperatively to grade their satisfaction as poor, no change, moderate, good, and excellent.

**Results:** The mean age was 51 years (range, 35–61 years), and the mean amount of fat aspirated was 30 mL (range, 10–200 mL). Five out of 55 patients (9.1%) developed tissue hardness that resolved with massage. All patients were followed up for a minimum of 6 months. Eighty-five percent of patients were satisfied with their contouring result and degree of skin tightening (48/55 patients). Two independent plastic surgeons considered the improvement in contouring and degree of skin tightening good to excellent in 52 of 55 cases.

**Conclusions:** In appropriately selected patients, RFAL neck and face contouring represent a safe procedure to achieve significant improvement of the skin laxity and fat deposits of the cervicofacial zone and jowls. (*Plast Reconstr Surg Glob Open* 2016;4:e850; doi: 10.1097/GOX.0000000000000809; Published online 24 August 2016.)

The purpose of our study is to present our experience and outcomes using radiofrequency-assisted liposuction (RFAL) technology in the neck region and facial contouring. RFAL is a relatively new technique that utilizes radiofrequency energy applied to the soft tissues in a bipolar manner, both internally as coagulative energy and externally as nonablative radiofrequency heating, to stimulate contraction and collagen formation by thermal effect to the skin while in the same time to coagulate and

liquify adipose tissue and stimulate profound contraction of the fibroseptal network (FSN).<sup>1–4</sup>

## MATERIALS AND METHODS

Fifty-five patients were enrolled in this study, who all underwent the RFAL procedure between November 2009 to November 2013 in the Central Clinic of Athens, Greece, and all procedures were performed by 2 certified plastic surgeons of our team, both very experienced in liposuction.

Inclusion criteria were male and female patients with fat and moderate skin laxity of the neck and jowls. Our patients, who were classified according to Baker classification,<sup>5</sup> were of type 1 and type 2. According to this classification, type 1 patients have slight cervical skin laxity with submental fat and early jowls, whereas type 2 patients have moderate cervical skin laxity, moderate jowls, and submental fat. All patients signed an informed consent preopera-

From the \*Kosmesis Aesthetic Plastic Surgery Center, Athens, Greece; and †Central Clinic of Athens, Athens, Greece.

Received for publication October 25, 2015; accepted May 17, 2016.

Copyright © 2016 The Authors. Published by Wolters Kluwer Health, Inc. on behalf of The American Society of Plastic Surgeons. All rights reserved. This is an open-access article distributed under the terms of the Creative Commons Attribution-Non Commercial-No Derivatives License 4.0 (CCBY-NC-ND), where it is permissible to download and share the work provided it is properly cited. The work cannot be changed in any way or used commercially.

DOI: 10.1097/GOX.0000000000000809

**Disclosure:** The authors have no financial interest to declare in relation to the content of this article. The Article Processing Charge was paid for by the authors.

tively, and they were asked to grade their result and their skin tightening and neck–face contours postoperatively in each follow-up visit using a 5-point scale as follows: 1, poor; 2, no change; 3, moderate; 4, good; and 5, excellent.

Finally, 2 independent plastic surgeons evaluated preoperative and postoperative pictures, 6 months after the operation, using the same evaluation system.

### Anesthesia

Eight patients underwent the procedure using local anesthesia. In 32 patients, a combination of local anesthesia and sedation was used, and in 15 patients, general anesthesia was used.

### Surgical Technique

The anesthetic infiltration used consisted of 1,000 mL Ringers lactate, 1.5 mL adrenalin 1:1000, 50 mL lidocaine 2%, and 10 mL bicarbonate. A 14-gauge infiltration cannula was used to deliver the solution to the subdermal plane until sufficient turgor was achieved. Sterile ultrasound gel was used to cover all the treated areas to lower the coefficient of friction for better movement of the device and better radiofrequency delivery. The depth of treatment was controlled by choosing the distance between the 2 electrodes before the operation, adjusting the desired level. Despite most of the articles recommending superficial heating, we treated the area of the neck at the level 5 or 6. We believe that delivering smaller energy (W) mainly to the deeper tissues could reduce the incidence of tissue hardening, yet it still could optimize the contraction of the quite important FSN.

### Devices

Because of the thin tissues in the cervicomental and jowl region, we used the special NeckTite cannula (Fig. 1A; Invasix, Yoki-nem, Israel) and the FaceTite hand piece (Fig. 1B; Invasix, Yoki-nem, Israel). The NeckTite cannula, which is internally coagulative and externally nonablative bulk heating, delivers the bipolar radiofrequency energy. The internal electrode is hollow with distal ports for simultaneous fat aspiration, coagulation, deep FSN, and the external electrode glides along the skin surface in tandem with the internal electrode, receiving radiofrequency from the internal electrode and delivering nonablative skin heating and tightening. The device has an external thermistor, high and low impedance, and no contact sensors and will turn off the radiofrequency when

the therapeutic target temperature has been reached or if there are potentially dangerous high or low tissue impedance readings or loss of epidermal contact. The NeckTite hand piece is 12 cm in length and 2.4 mm in diameter. In 7 patients, we treated the face with the FaceTite applicator. The FaceTite hand piece is 10 cm in length, 1.7 mm in diameter, and a solid, nonaspirating, bipolar radiofrequency device for subdermal coagulative heating and transdermal nonablative radiofrequency skin tightening. There is no hole for fat aspiration in this cannula.

### Neck Positioning

The neck was divided into 3 areas: 2 lateral (II and III) and 1 medial (I; Fig. 2). We applied the RFAL hand piece separately to each area. After treating all 3 zones, we then aspirated the fat with a 3-mm neck spatula. The procedure was performed through 3 stab incisions: 1 in the submental area and 1 each in the lower part of each ear lobe. For the lower face, we used the incisions behind the ear lobes.

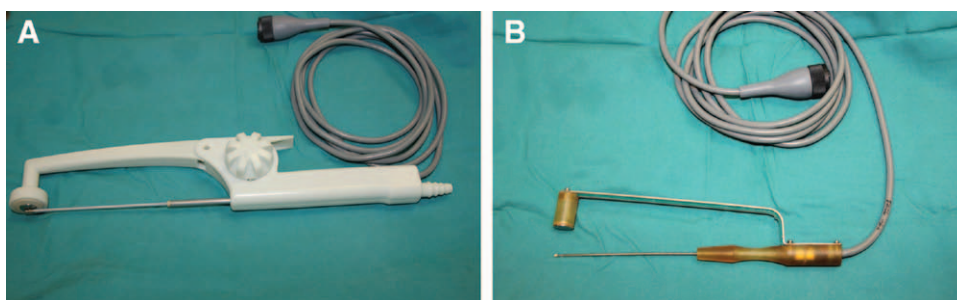
### The Parameters and Tissue End Points

The radiofrequency power was 15 W, and the epidermal cutoff temperature was 38°C. When the temperature of 38°C was reached, the radiofrequency energy was automatically cut off. The moment the soft-tissue temperature was 0.1°C below 38°C, the radiofrequency energy was automatically turned on again. This automatic feedback loop of target temperature–controlled radiofrequency allows the surgeon to maintain uniform tissue temperature for prolonged periods of time. We continued treatment on the area for 1 minute continuously, once the thermal end point has been reached. For the FaceTite applicators, the power of radiofrequency was 10 W, and the cutoff temperature was again 38°C.

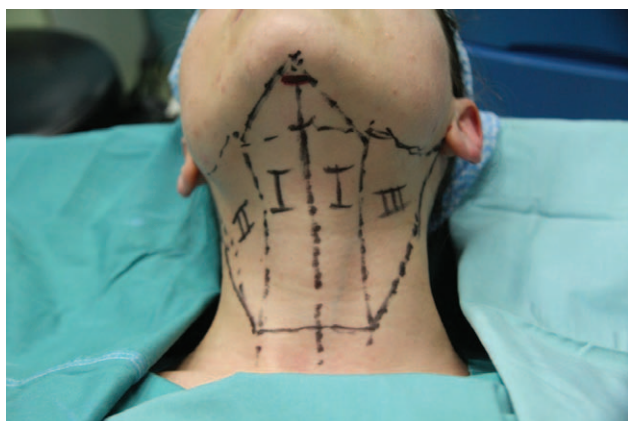### Postoperative Care

A face and neck compression garment was worn for 2 days. The average NeckTite operative time was 45 minutes (25 minutes to 1 hour). The average total aspirated fat volume was 30 mL (10–200 mL). The average time for the lower face FaceTite (except for the head and eyes) was 15 minutes.

- Fifteen patients had treatment for their lower face and neck.
- Eight patients had on their neck laxity without fat aspiration.



**Fig. 1.** NeckTite applicator and FaceTite applicator.



**Fig. 2.** Preoperative neck area design for treatment.

The RFAL delivers radiofrequency converted into heat, estimated in kilojoules. The mean amount of energy delivered was 4.5 kJ per procedure (2–8.5 kJ).

## RESULTS

Fifty-five patients underwent RFAL on the neck and lower face area. The mean age of the patients was 51 years (range, 35–61 years old). The mean body mass index was 25 (range, 21–29 kg/m<sup>2</sup>). The mean amount of energy delivered was 4.5 kJ (2–8.5 kJ). The maximum temperature was 38°C. The average operating time was 45 minutes.

The majority of the patients returned to work in 2 days. Twenty percent of the patients were extremely happy with results, 42% considered the results good, and 23% were satisfied, whereas 15% were considering the results poor or no change, and half of these patients had a neck lift 4 to 8 months later. In aggregate, the RFAL nonexcisional tightening resulted in 85% of patients satisfied, happy, or extremely happy, whereas 15% were dissatisfied with the degree of soft-tissue contraction.

The independent plastic surgeons evaluation of photographs showed 12% excellent results, 35% good results, 48% moderate, and 5% poor. In aggregate, independent surgeons, familiar with neck rejuvenation procedures, scored the 6-month cervicomenal and/or lower facial outcomes as moderate to excellent in 90%

of the cases, whereas poor contour results only in 5% of the cases.

There were no major complications as there were no adverse events that required further medical or surgical intervention. There was a 3.6% incidence (2/55) of thermal injury. These 2 small full-thickness burns measured 5 mm × 5 mm, occurred with the NeckTite applicator, and both of which were treated with local wound care and left inconspicuous scars. Both of these burns, 1 for each surgeon, occurred in their first 5 cases.

Five of 55 NeckTite patients (9.1%) developed hardness of the subcutaneous tissue of the neck, which was resolved in all cases with massage after 3 months. One patient developed transient paralysis (paresis) of the marginal mandibular branch of the facial nerve, which resolved 2 months later. There were no complications with the FaceTite applicator.

## Case Studies

### Case 1

We discuss the case of a 58-year-old woman with moderate skin laxity and fat in the neck and submental areas (Figs. 3–5).

Treatment of lower face also.

Anesthesia: local + sedation

Device NeckTite: power, 15 W; temperature, 38°C; and total energy delivered, 5.2 kJ

Device FaceTite: power, 10 W, temperature, 38°C; total energy delivered, 1.5 kJ

Total energy: 6.7 kJ

Surgical time: 48 minutes

Aspiration: 60 mL of fat

### Case 2

We discuss the case of a 48-year-old woman with skin laxity and adipose tissue (Figs. 6–7).

Anesthesia: local + sedation

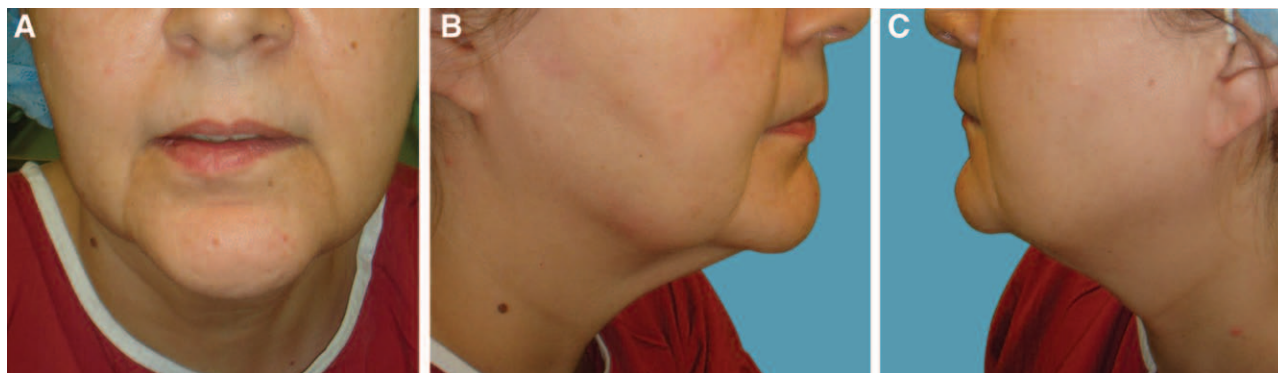Device NeckTite: power, 15 W; temperature, 38°C; total energy 8 kJ

Device FaceTite: power, 10 W; temperature, 38°C; total energy 2 kJ

Total energy: 10 kJ

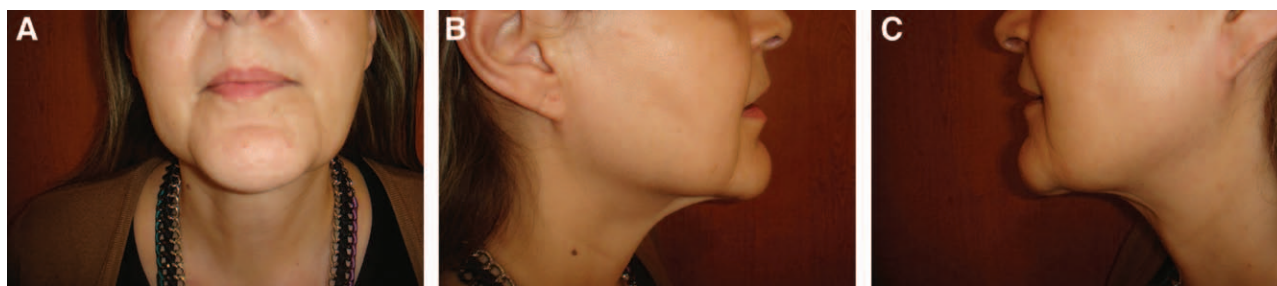Surgical time: 50 minutes

Fat aspiration: 55 mL

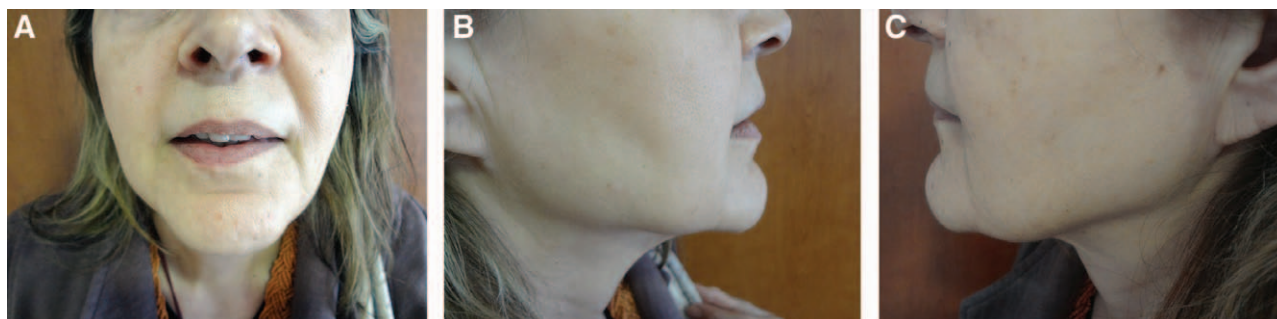

**Fig. 3.** Preoperative pictures—case 1: front view (A), lateral right view (B), and lateral left view (C).

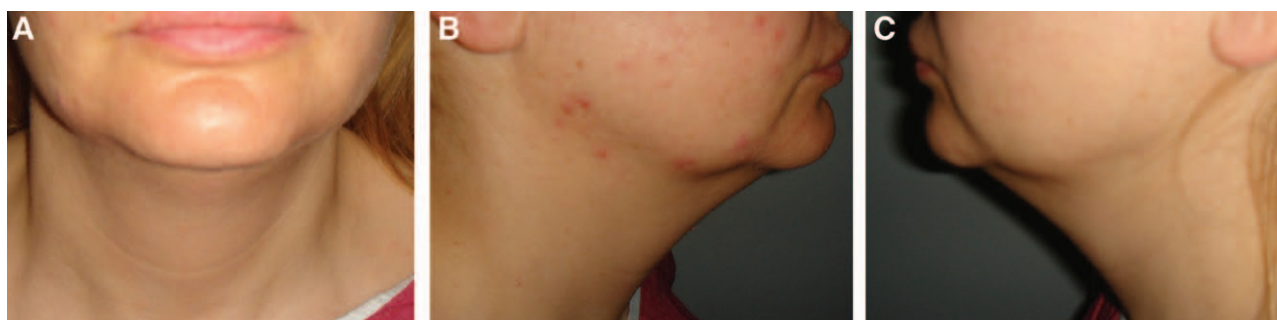



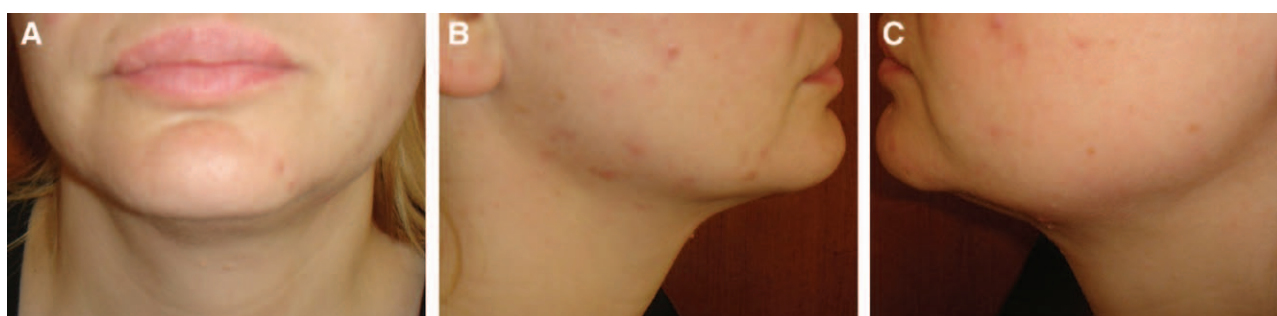**Fig. 4.** Postoperative (1 year) pictures—case 1: front view (A), lateral right view (B), and lateral left view (C).



**Fig. 5.** Postoperative (2 years) pictures—case 1: front view (A), lateral right view (B), and lateral left view (C).



**Fig. 6.** Preoperative pictures—case 2: front view (A), lateral right view (B), and lateral left view (C).



**Fig. 7.** Postoperative (1 year) pictures—case 2. Observe the remarkable improvement of the jowls: front view (A), lateral right view (B), and lateral left view (C).

## DISCUSSION

The desire of patients for aesthetic cervicofacial antiaging improvements with the less invasive and traumatic techniques have led doctors and the energy device industry to develop novel approaches that are leaving almost no scarring and offer very minimal downtime and satisfactory results.

This study evaluates and reports the efficacy of the RFAL in the neck region, in the largest reported series of NeckTite and FaceTite RFAL treatments to date, to the best of our knowledge, in this anatomic regions.

Most cervicofacial RFAL procedures were easily performed under local anesthesia. If they were combined with

other procedures in different anatomic areas, general anesthesia was administered. Wet or superwet anesthesia was applied in all treated neck areas before the application of RFAL. No additional excision of skin or subcutaneous tissue was performed after the RFAL application, only suction with a blunt spatula type to remove any remaining fatty tissue was required.

RFAL technology has been widely applied over the last few years with good results in several areas of the body. Numerous peer-reviewed articles confirm soft-tissue contraction of up to 34% over 12 months, compared with only 6% for suction-assisted lipoplasty (nonthermal).<sup>2</sup> Laser-assisted liposuction also provides thermal stimulation and demonstrated a modest contraction of 17% at 6 months and but lacks external automated epidermal temperature-controlled thermal stimulation, making it potentially more risky in thin tissue regions, like the neck and face.<sup>6</sup> Physicians are enabled to offer less invasive RFAL procedures, where, in the past abdominoplasty, thigh, arm, or neck lift might have been offered. Overweight patients treated with RFAL were the subject of the study performed by Hurwitz and Smith. Seventeen patients, with a mean body mass index of 27 kg/m<sup>2</sup>, were treated with RFAL followed by classic suction of the remaining fat in the abdomen, arms, thighs, knees, and trunk. The mean aspirated volume was 1,759 mL, with 3-dimensional scanning documenting the changes in body figure and skin contraction. However, there were no neck area cases included in this study.<sup>3</sup> Theodorou et al reported the effects of RFAL in a large series of patients under local anesthesia in the abdomen, flanks, back, chest, thighs, and arms with satisfactory to very good results in the improvement of body contour and skin tightening. There was 1 case in the neck region included in this specific study.<sup>7</sup> Furthermore, they reported another 40 patients who were treated for arm contouring with good to excellent results, using RFAL only under local anesthesia.<sup>4</sup>

Mulholland and coworkers<sup>8</sup> reported on a series of 22 patients the advantages of RFAL in temperature-controlled radiofrequency heating efficiently, safely, and uniformly a significant amount of tissue and at the same time creating significant contraction and retraction of the underlying tissues, but the areas included were again the abdomen, flanks, male breasts, outer and inner thighs, and hips. Mulholland and Kreindel<sup>9</sup> has described the efficacy of RFAL technology on the face on a series of 10 patients using the FaceTite hand piece to treat brow, jawline, submental, and lower lid laxity, showing good results in this small series. The RFAL provided significant tightening of the skin in all treated areas. Later on, a bigger series was reported by Ahn et al,<sup>10</sup> using the FaceTite hand piece for nonexcisional facial tightening with good results.

The actual thermal effect that radiofrequency energy provides is to coagulate the adipose, fibrous, and vascular tissue and cause liquefaction of the fatty tissue that is simultaneously aspirated by the internal electrode, which is also a blunt tip, silicon-coated cannula. The significant soft tissue contraction following RFAL treatment occurs in 2 ways: (i) most contraction with the NeckTite occurs through a strong thermally mediated shortening of the

FSN with the coagulative pericannalicular temperatures of 85°C, and (ii) the external electrode provides a nonablative dermal stimulation of 50 to 55°C subdermally for non-coagulative collagen stimulation. The FaceTite uses strong coagulative temperatures to stimulate the deep reticular dermis through coagulation of the subdermal fat.

The thermal stimulation of the upper dermis and shortening effect to the FSN<sup>8,10,11</sup> contribute to collagen contraction and soft-tissue tightening in a degree that even severe skin laxity can be treated safely in the submental area and adjacent regions. In addition, the embedded thermal sensor within the external electrode achieves a more targeted and uniform temperature distribution without any red spots and a reduced risk of thermal injuries or untreated areas such as those found in laser-assisted liposuction.<sup>12–14</sup>

The combination of the above RFAL features make NeckTite and FaceTite useful tools for the treatment of challenging areas of laxity, with or without fat, such as the restoration of the youthful neck and jawline. In the neck area, often the fat accumulation is not as prominent as the skin laxity that prevails and removal of any fat without thermal contraction or excision would result in an older cervicomental contour.

We found that the excess fat of the submental region was efficiently aspirated at the same time with the RFAL application, and the contribution of traditional liposuction in the end, for contour refinement, was deployed in 30 cases to remove the remaining liquefied fat better. The RFAL skin contraction removes the need for superficial liposuction and the contour irregularities and high complication rate that can occur with this technique.

In our series, 8 of 55 patients presented only neck skin laxity without any fat accumulation. We treated them using the neck and face hand piece, in combination. Our results were quite satisfactory. However, a higher number of cases are needed to achieve a standardized procedure with repetitive results for these particular problems.

Five of 55 (9.1%) patients developed temporarily induration and firmness of the soft tissue of the neck that remained for about 3 months, but fully recovered by persistent, daily massage. We recommend deeper application of the device and low energy up to 15 W. We think that the superficial application of high temperature can create this type of hardening, which could become quite frustrating for the patients and for the doctors to resolve. Smaller energy and deeper application of the device can prevent the hardening of the tissue. On the other hand, we can achieve the tightening of the skin through the FSN. The energy is transferred through the FSN to the subdermal plexus, and so, we can achieve the tightening.<sup>8</sup> Another alternative would be to use the NeckTite deep to coagulate the fat and vessels and stimulate adipose FSN contraction and then use FaceTite superficially and subdermally.

The majority of the patients were satisfied with the results; however, 15% of the patients were unhappy because they were expecting much more improvement with this technique. They considered that the skin contracture or neck contouring achieved were not of their expectation/satisfaction.

There is a definite learning curve with this technology, as evidenced that the 2 minor thermal injuries (1 for each surgeon) occurred in the first few cases. Hands-on-training preceptorship is recommended and then beginning with larger body cases and practicing on abdominoplasty tissue precession with the smaller NeckTite and FaceTite applicators and after that to start working in the neck and face with conservative parameters.

Ninety percent of our patients were older than 40 years (when usually neck aging is getting obvious), and 45% of them were older than 50 years, with even more severe problems of skin laxity, and consequently, to achieve satisfactory to good neck-contour correction is even more challenging without open surgery. Considering the difficulty of this task and results achieved with the only use of RFAL, we conclude that it is a very promising treatment for these areas and a good alternative to open, excisional surgery, with long-lasting results in selected patients.

## CONCLUSION

RFAL performed in the neck region is a safe and reliable method of treating the aesthetic problems of the aging neck, under local wet or superwet anesthesia, sedation, or general anesthesia when combined with procedures on other parts of the face and body.

**Stavroula Rodopoulou, MD**

Kosmesis Aesthetic Plastic Surgery Center  
Ethnikis Antistaseos 9-11 Street  
Athens 15232, Greece  
E-mail: villyro@yahoo.com

## REFERENCES

1. Mulholland RS. Nonexcisional, minimally invasive rejuvenation of the neck. *Clin Plast Surg*. 2014;41:11–31.
2. Duncan DI. Nonexcisional tissue tightening: creating skin surface area reduction during abdominal liposuction by adding radiofrequency heating. *Aesth Surg J*. 2014;33:1154–1166.
3. Hurwitz D, Smith D. Treatment of overweight patients by RFAL for aesthetic reshaping and skin tightening. *Aesth Plast Surg*. 2012;36:62–71.
4. Theodorou S, Chia C. Radiofrequency-assisted liposuction for arm contouring: technique under local anesthesia. *Plast Reconstr Surg Glob Open* 2013;1:e37.
5. Baker DC. Lateral SMASectomy, plication and short scar facelifts: indications and techniques. *Clin Plast Surg*. 2008;35:533–550.
6. Dibbernardo B. Randomize, blinded split abdomen study evaluating skin shrinkage and skin tightening in laser-assisted liposuction versus liposuction control. *Aesthetic Surg J*. 2010;30:593–602.
7. Theodorou SJ, Paresi RJ, Chia CT. Radiofrequency-assisted liposuction device for body contouring: 97 patients under local anesthesia. *Aesth. Plast Surg*. 2012;36:767–779.
8. Paul M, Blugerman G, Kreindel M, et al. Three-dimensional radiofrequency tissue tightening: a proposed mechanism and applications for body contouring. *Aesth Plast Surg*. 2011;35:87–95.
9. Mulholland RS, Kreindel M. FACETITE: subdermal radiofrequency skin tightening and face contouring.
10. Ahn DH, Mulholland RS, Duncan D, et al. Non-excisional face and neck tightening using a novel subdermal radiofrequency thermocoagulative device. *J Cosmet Dermatol Sci Appl*. 2011;1:8845–8851.
11. Divaris M, Boissic S, Brachet M, et al. A clinical and histological study of radiofrequency-assisted liposuction (RFAL) mediated skin tightening and cellulite improvement. *J Cosmet Dermatol Sci Appl*. 2011;1:36–42.
12. Waldman A. *Comparison of Treatment Uniformity of Laser Assisted Liposuction (LAL) and Radiofrequency Assisted Liposuction (RFAL): Scientific Report (PhD)*. Israel.
13. Paul M, Mulholland RS. A new approach for adipose tissue treatment and body contouring using radiofrequency-assisted liposuction (RFAL). *Aesth Plast Surg*. 2009;33:687–694.
14. Alexiades-Armenakas M. Combination of laser-assisted liposuction and minimally invasive skin tightening with temperature feedback for treatment of the submentum of the neck. *Dermatol Surg*. 2012;38:871–881.